

Sri Lanka Journal of Forensic Medicine, Science & Law

e-ISSN 2465 – 6089
Vol. 7 No. 2 - December 2016
Biannually

CONTENTS

- | | |
|---|-------|
| 1. Editorial
Chain of custody in forensic practice: The need for standard of practice guidelines in Sri Lanka.
<i>Induwara Gooneratne</i> | 1-2 |
| 2. A current need for modern instruments in forensic pathology: A way forward.
<i>Paranitharan P., Hulathduwa S.R.</i> | 2-5 |
| 3. A sudden death following cardiomyopathy in a child.
<i>Perera W.N.S., Mahendra B.A.G.G.</i> | 6-10 |
| 4. Estimation of stature from foot outline in adult Malaysian malayalee ethnics for forensic investigation.
<i>T.Nataraja Moorthy & Rasvini Asogan</i> | 11-20 |
| 5. A dermatological induced attempt by a husband to make his estranged wife leave home.
<i>Jayasooriya R. P., Sivasubramaniam M., Chandrakirthi, W. A. N</i> | 21-23 |
| 6. Forensic art: 2D facial composite through image processing techniques in Sri Lanka.
<i>Sivaneasharajah L., Perera M.A.S., Jayasekara P.B., Perera J., Karunaratne D.D., Sandaruwan K.D., Rajapakse R.N.</i> | 24-27 |
| 7. A review of the use of spheno-occipital synchondrosis as an age indicator and its implications for Sri Lanka
<i>Induwara Gooneratne</i> | 28-31 |
| 8. Instructions to Authors | 32-33 |



Official Publication of the Department of Forensic Medicine
Faculty of Medicine, University of Peradeniya
Sri Lanka



Medicine
Sri Lanka Journal of Forensic Science & Law

A peer reviewed journal
Published by Faculty of Medicine, University of Peradeniya, Sri Lanka

Editor

Dr. Induwara Gooneratne
Dept. of Forensic Medicine, Faculty of Medicine
University of Peradeniya,
Sri Lanka

Tel. 094-81-2388083
E-mail : induwarag@yahoo.com

Editorial Board

- Prof. Ravindra Fernando, MBBS, MD, FCCP, FCGP, FRCP (London), FRCP (Glasgow), FRCP (Edinburgh), FRCPath (UK), DMJ (London)
Senior Professor
Dept. of Forensic Medicine & Toxicology, Faculty of Medicine, University of Colombo
- Dr. L.B.L. De Alwis, MB, BS (Cey), DLM (Colombo), MD (Colombo)
Chief Consultant JMO (Retired), Colombo
Institute of Legal Medicine and Toxicology, Francis Road, Colombo 08
- Dr. Collin Seneviratne,
BSc, MSc, PhD (UK), MFSSoc
Forensic Toxicologist, ROAR Forensics, Malvern Hills Science Park, Geraldine Road,
Worcestershire, WR14 3SZ, United Kingdom
- Dr. Induwara Gooneratne,
BDS, Dip. in Forensic Medicine, MSc, MPhil (For.Med), LLM (USA), DTox, DHR, Attorney-at-Law
Dept. of Forensic Medicine, Faculty of Medicine, University of Peradeniya, Sri Lanka
- Dr. Dinesh Fernando, MBBS, MD, DLM, DMJ (Lon.)
Dept. of Forensic Medicine, Faculty of Medicine, University of Peradeniya, Sri Lanka
- Dr.(Mrs) D.H. Edussuriya, MBBS, MPhil (For.Med.), PhD
Dept. of Forensic Medicine, Faculty of Medicine, University of Peradeniya, Sri Lanka
- Dr. Amal Vadysinghe, MBBS, DLM, MD (Col.), D-ABMDI (USA)
Dept. of Forensic Medicine, Faculty of Medicine, University of Peradeniya, Sri Lanka
- Prof. K.A.S. Kodikara, MBBS, MD, DLM, Attorney-at-Law
Dept. of Forensic Medicine, Faculty of Medicine, University of Peradeniya, Sri Lanka

International Advisory Board

- Prof. Corrine Parver, JD
Professor of Health Law & Director, Health Law & Bio Ethics Project
American University, Washington DC, U.S.A.
- Prof. Derrick Pounder, MB, ChB, FRCPA, FFPPathRCPI, MRCPath, FHKCPath
Professor & Director
Centre for Forensic & Legal Medicine, University of Dundee, UK
- Prof. D. Ubelaker, PhD, DABFA
Consultant to FBI & Adjunct Professor
Smithsonian Institute, Washington DC, U.S.A.
- Prof. Michael S. Pollanen, MD, PhD, FRCPath, DMJ (Path), FRCPC
Chief Forensic Pathologist

This journal is indexed in DOAJ, IMSEAR, Index Medicus & Google Scholar

EDITORIAL

Chain of Custody in Forensic Practice: The Need for Standard of Practice Guidelines in Sri Lanka.

Induwara Gooneratne

Department of Forensic Medicine, Faculty of Medicine, University of Peradeniya, Sri Lanka

This article discusses the notion of 'chain of custody' in forensic practice and its significance in the law of evidence. The need for this discussion arose from the numerous newspaper articles and blogs that highlighted and critiqued handling of forensic samples in Sri Lanka especially related to a recent case that is under investigation.

As the name suggests a chain of custody means the chain/authority under which forensic evidence or a sample has been in custody. Simply put, under whose custody and at which point of time were the forensic samples under consideration. This important concept serves three purposes in evidence law related to criminal investigations. First, it provides details of the official personal under whose hands the samples were and when. It also provides details of the official personal who handled the samples next and so on until it arrives its final destination. In maintaining proper chain of custody, it is a must that all forensic personal properly documents receiving and dispatching of the samples. What I mean by proper documentation is one that is clear, precise, coherent, comprehensive, integral, retrievable and protected. What I mean by it being protected is that the means of record should be kept confidential and protected so that there is minimal or no opportunity for an outsider or an unwanted insider to alter details, mishandle specimen or misplace the register.

The minimum details that should be included in the registry are the case number or reference, sample type, volume/weight, date and time of collection, the person collected, whether the sample is sealed and by whom, date and time of dispatch, the carrier, the place to where the sample was dispatched, reason for dispatching, how it was dispatched, who dispatched it, name,

signature, date and time of receiving the sample by the receiving end. One common error that occurs in Sri Lankan labs is that there is only a signature and there is no name when the samples are received. The issue that can arise here, especially when there are short signatures or false signatures by people who receive the samples. Therefore, it is important that both the sender's name with signature and the receiver's name and signatures are clearly stated in the registry. If properly done, this ensures that the sample analysed was actually the sample that was collected. In other words there was no mishandling or contamination of the samples during its course of transport. Of course, this assumption relies heavily on the credibility of the practitioners and the sample handlers in the registry. If all in the chain of custody are to be believed then, it can be discerned that the sample was uncontaminated. However this doesn't negate the possibility of others other than the signatories in the registry have access to the samples. This so happens when there are groups of people working together and only one or a few sample storing places are available for example a refrigerator. Further, it is possible that the cleaners or the labourers have access to these facilities. It is up to the forensic unit concerned to develop their own guidelines and standard of practice (SOPs) to uphold the integrity of chain of custody. It is therefore essential that the staff is trained in this regard and that there is some kind of accounting or auditing process in place.

It is seen at many instances in Sri Lanka that the labourers are sent with the samples. And, labourers are utilised to dispatching and receiving of samples. It is always better that people with some training are designated to handle these specimens as they are required to be handled with caution.

Chain of custody as a legal notion assumes the integrity of the sample obtained initially. If properly maintained it assumes that the sample originally collected is the one that is received by the laboratory for analysis. It further assumes that the sample collected originally was faithful and that the sample received for analysis and being analysed is in its current form and a true representative of the original sample. It is practically possible that the sample is deteriorated or decomposed due to delaying that took place at the original end or due to some issue in collection, store or transport. However unfortunately the status of the sample is not recorded in a routine chain of custody and therefore it is difficult to opine on the integrity of the sample so affected by the environmental insult, improper transport or storage etc. It is the responsibility of each forensic unit to consider these aspects and develop guidelines to collect transport and preserve specimens as necessary.

Most of the guidelines if at all are addressing the external chain of custody. However, it is of paramount importance that a forensic unit with multiple disciplines or with multiple experts develop an internal chain of custody mechanism and a standard of practice. Most forensic units in Sri Lanka do not seem to have either an external or internal standard of practice on the chain of custody. The national level issues raised in courts and media on the internal and external chain of custody of forensic specimen warrants a standard of practice and guidelines in maintaining proper chain of custody to both administer justice and to maintain scientific integrity.

One fact the forensic practitioners ignore is the amount of dismissal of criminal cases based on unavailability of proper evidence. As regard to circumstantial evidence most forensic samples belong, a high degree of credibility is required by the standard of proof in a court room in order to establish the ultimate or penultimate

probanda relevant to the case. Therefore a doubtful procedure of chain of custody can easily create a defence and lead to a dismissal of a case.

Another aspect in the chain of custody is the maintenance of either the volumetrics or weights as relevant to the sample. In this way it is possible to examine how much of sample has been taken for analysis and how much then should be left in the sample. It is also possible to audit who has taken the sample for analysis and how much and whether the remaining is kept under optimal conditions if a second opinion or second analysis is ordered or required. Internal guidelines of chain of custody should take this aspect also into consideration.

It is timely that we develop a favorable attitude amongst forensic practitioners regarding the maintenance of both external and internal chain of custody in Sri Lanka. It is also important that we develop knowledge about these aspects among the lawyers and judges especially for them to scrutinize the procedure in their cross examination in court. Training of the people along this most important forensic link is the next important task one needs to look at. Whether the practitioners are trained in maintaining a chain of custody, whether the forensic units have adequate facilities infrastructure and man power, whether the forensic laboratory are periodically checked for protocol awareness or whether there is an internal or external audit on the adherence to the standards of practice protocols and whether the standard of practice guidelines are valid in the eyes of evidence law are a few relevant questions one needs to carefully consider in developing these standard of practice guidelines in maintaining chain of custody in forensic practice. Besides what repercussions are proposed to a practitioner who malpractice accepted protocols should also be given due consideration in formulating guidelines.

A CURRENT NEED FOR MODERN INSTRUMENTS IN FORENSIC PATHOLOGY: A WAY FORWARD

Paranitharan P.¹, Hulathduwa S.R.²

¹Department of Forensic Medicine, Faculty of Medicine, University of Kelaniya,

²Senior Lecturer, Department of Forensic Medicine, University of Sri Jayewardenepura, Sri Lanka

ABSTRACT

Routine dissection of the cadaver followed by mandatory and ancillary investigations is still the most widely used method in forensic autopsy throughout the globe. In contrast to most other disciplines of medicine, instruments used in routine autopsy work remain plain, simple, unsophisticated and virtually unchanged for over a century. Incorporation of modern technology to improve these instruments to meet the new challenges such as minimizing the risk of bio-hazards, acquisition of precision in dissection, facilities for simultaneous imaging, sampling and archiving the information and finally making the dissection a less cumbersome task with lesser degree of dependability on individual human skills has become the need of the day. The authors briefly discuss few initiative steps taken along this long pathway.

Key words: *forensic pathology, modern instruments, advanced techniques, human cadaver.*

Corresponding author:
paran28@gmail.com

INTRODUCTION

Forensic Pathology is entering a new era. The credit mainly goes to few individuals who had established world class forensic centres in Canada, Australia, North America, England and Switzerland. However, standard instruments used in prosecution of the human

cadaver remain the same without much modification since the time known. Though great strides had been made to supplement the conventional autopsy by means of *virtopsy*; the requirement for the standard dissection of the cadaver to arrive at a cause of death and to address various other medico-legal issues still remain much the same. This phenomenon is more visible in the less developed parts of the world and this situation cannot be expected to be drastically changed in the near future.

Purpose of this report

The standard instruments currently used for dissection - the scalpel, scissors, brain knife and the saw can very well serve the required purposes. However, considering the astonishing advances of modern equipment, techniques and instruments in most other branches of medicine, the authors feel that a new array of modern instruments needs to be developed for routine autopsy purposes to address health and safety issues of the staff, achieve greater precision in dissection technique (including evisceration), minimize the hazels and cumbersomeness of the routine procedures and incorporate new technology in to the routine procedure such as digital imaging and storage. The main purpose of this article is to propose how the existing instruments could further be modified to achieve the above goals and to innovatively suggest how introduction of new instruments could take routine dissection procedure to greater heights.

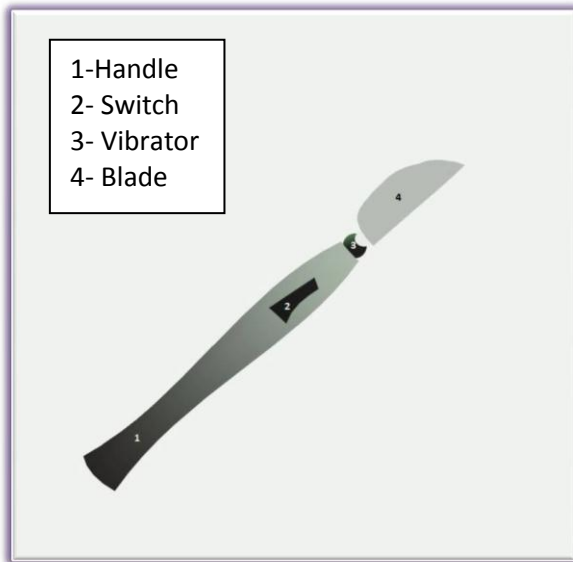


Figure 1: Electric Scalpel

As an example, the scalpel routinely used to dissect human cadaver, including sectioning of the calcified or non-calcified coronary arteries, could be modified into a battery operated one with incorporation of an electric motor between the handle and blade which would oscillate the blade to make the necessary dissections in a controlled manner. This simple modification would pave the way for a scalpel which is better designed and user friendly.




Figure 2: Modified Electric Saw

The electric saw, currently used for cutting the human skull to expose the brain, could be modified to a more user friendly, health and safety equipment specially designed for human skull removal and vertebral dissection. An installed program will be used to automatically determine the cutting depth of the blade when dissecting the human skull or vertebrae to prevent damage to the brain or the spinal cord. Similarly, the negative pressure tubing will collect the “bone dust” to a separate compartment in the handle, minimizing the health hazard especially in suspected prion diseases. It is also suggested to replace the metal handle with an electrocution resistant material. A smaller version of an electric saw similar to a “can opener” could be devised for finer dissections of the base of the skull (for example, the removal of the pituitary gland or the middle ear) and other skeletal structures elsewhere on the body.

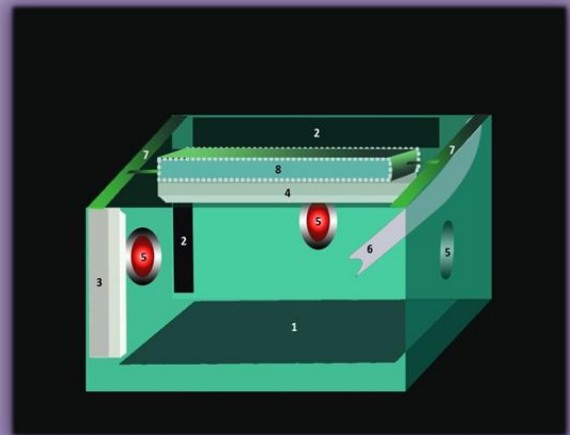


Figure 3: Multi Purpose Brain Dissector

The novel equipment where much sophistication is achieved by incorporation of modern technology would be the multipurpose brain dissector. This equipment is designed in such a way that a human brain, once taken out from the cranial cavity, would be scanned, photographed, dissected (with or without cerebral angiography) and necessary tissue samples taken. This is planned to minimize the manual usage of the conventional brain knife and to overcome some drawbacks in standard dissection. This equipment is operated by a computer program

and necessary instructions would be provided through a computer to select the required function and to operate the robotic arm. The computer also provides facilities for image archiving simultaneous with dissection of each slice or anatomical part of the brain.

CONCLUSION

The combined efforts of the forensic pathologists, medical equipment manufacturers and interested parties from other relevant specialties with technological expertise in developing newer instruments would take the dissection techniques to great heights turning the routine autopsy procedure in to a pleasant and more fertile experience.

ACKNOWLEDGEMENT

Our thanks go to Dr. M.I. Jayaweera and Dr. P.N. Managoda of the Faculty of Medicine, Ragama for their secretarial assistance.

LIMITATIONS

The authors clearly wish to indicate that the above mentioned instruments are purely conceptualized ideas derived from already existing instruments. The ideas were never tested to see the feasibility of production. However, the scientific thinking would open doors for future expanded ideas and production of user friendly instruments.

REFERENCE

1. Forensic Medicine from old problems to new challenges: 2011. Chap 14. Duarte Nuno Vieira.
2. www.mopec.com [last accessed on 5.2.2015]
3. www.meder.com [last accessed on 5.2.2015]
4. Jacopo A, Natalie M, Hauke B, Paul M, Colleen S et al. Postmortem examination of patient H.M.'s brain based on histological sectioning and digital 3D reconstruction. *Nature Communications* 5, Article number: 3122. doi:10.1038/ncomms4122.

A SUDDEN DEATH FOLLOWING CARDIOMYOPATHY IN A CHILD

Perera W.N.S.¹, Mahendra B.A.G.G.²

¹Department of Forensic Medicine, ²Department of Pathology, Faculty of Medicine,
University of Kelaniya, Sri Lanka.

ABSTRACT

Introduction

Paediatric cardiomyopathies are clinically heterogeneous heart muscle disorders responsible for a significant morbidity and mortality. Phenotypes include hypertrophic, dilated, restrictive and arrhythmogenic right ventricular cardiomyopathy. The aetiology is diverse and includes genetic and non-genetic causes. Restrictive cardiomyopathy (RCM) is uncommon in children, accounts for 5% of all cardiomyopathies and has the worst prognosis.

Case Report

An eight-year-old girl with a history of syncopal attacks over one year, developed acute dyspnoea. She had a cardiac arrest on admission and died despite resuscitation. Her past clinical records showed an echocardiogram report revealing biventricular diastolic dysfunction, good ventricular systolic function, biatrial dilatation and biventricular hypertrophy. Myocardial biopsy showed mild interstitial fibrosis. She had been diagnosed as having RCM. At autopsy the heart weighed 210g with biatrial dilatation, symmetrical biventricular wall thickening (both right and left ventricular wall thickness 18mm) and subendocardial fibrosis. The histology of the myocardium revealed hypertrophy and mild disarray of myocytes and interstitial fibrosis. There was no amyloid or iron deposits, granulomas or tissue eosinophilia. Cause of death was ascertained as acute cardiac failure following cardiomyopathy.

Discussion and Conclusion

RCM is a disease characterized by a primary decrease in ventricular compliance resulting

in diastolic failure. This patient had classic functional and structural features of RCM which include biventricular diastolic dysfunction, good ventricular systolic function and biatrial dilatation. An increased biventricular wall thickness which is a classic feature of hypertrophic cardiomyopathy (HCM) suggests clinical overlap with HCM. Mixed phenotype of RCM/HCM has shown significant transplant free survival compared to pure RCM. Relatively less symptoms and longer survival in this child could be explained by mixed RCM/HCM phenotype.

Key words: Cardiomyopathy, Paediatric, Restrictive

Corresponding author:
nirperera2000@yahoo.com

INTRODUCTION

Paediatric cardiomyopathies are clinically heterogeneous heart muscle disorders¹ associated with cardiac dysfunction and responsible for a significant morbidity and mortality². Phenotypes include hypertrophic, dilated, restrictive and arrhythmogenic right ventricular cardiomyopathy³. The aetiology is diverse and include both genetic and non-genetic causes⁴. Restrictive cardiomyopathy (RCM) is uncommon in children, which accounts for approximately 5% of all cardiomyopathies and has the worst prognosis². Rarity of this condition in childhood limits the knowledge on disease process and its outcome.

CASE REPORT

An 8-year-old girl who had a history of syncopal attacks over one year period, developed sudden onset dyspnoea and cardiac arrest. In spite of resuscitation she died and the cause of death was ascertained as complications of cardiomyopathy.

There was no history of congenital disease or sudden deaths in her family.

She had been investigated for recurrent syncopal attacks over the past one year. Perusal of the initial clinical records revealed cardio-thoracic ratio (CTR) of 55%, normal cardiac valves, biventricular hypertrophy, trivial mitral and tricuspid regurgitation with no right or left ventricular outflow obstruction. At this point the patient had been diagnosed as having hypertrophic cardiomyopathy (HCM).

She had been investigated further as the syncopal attacks were continuing. The investigations has revealed elevated proBNP (pro-brain natriuretic peptide) of 5861pg/ml, normal renal function and normal eosinophilic count. The CTR had increased to 65%. Echocardiogram showed biventricular diastolic dysfunction, good ventricular systolic function, pulmonary plethora and systemic venous congestion. Myocardial biopsy had shown mild interstitial fibrosis and the diagnosis had been revised as RCM. She had been managed conservatively.

At autopsy the enlarged heart weighed 210g, showed biatrial dilatation and symmetrical biventricular wall thickening with no dilatation of the ventricles. Both right and left ventricles measure 18mm in thickness. The myocardium was firm with marked sub endocardial fibrosis (Figure 1). The valve cusps were irregular and firm with fibrotic and shortened chordae tendinae. The coronary arteries were normal.

The histology showed myofibre hypertrophy and disarray (Figure 2). There was diffuse interstitial fibrosis with prominent subendocardial fibrosis (Figures 3 and 4).

There was no amyloid or iron deposition, granulomas or tissue eosinophilia.

The lungs and the liver showed vascular congestion. Other organs were unremarkable. The cause of death was ascertained as acute cardiac failure following cardiomyopathy.

DISCUSSION

Cardiomyopathy is a clinically heterogeneous disease in which myocardium itself is structurally and functionally abnormal⁶. In paediatric population, 40% of children with cardiomyopathy needs transplantation within 5 years of diagnosis otherwise they progress to death². Paediatric cardiomyopathies have a genetic and non-genetic aetiology⁶. Majority of the cases are still considered idiopathic as aetiopathology of this disease is not completely elucidated⁵. RCM is characterized by impaired ventricular filling and reduced diastolic volume of ventricles with near normal systolic function⁷. Main structural changes are atrial dilatation, normal ventricular wall thickness and normal atrioventricular valves⁸.

Hypertrophy of ventricular wall is a characteristic feature of HCM. In HCM the ventricular wall thickening could be asymmetrical or diffuse and symmetrical. Similar to RCM, HCM is also characterized by diastolic dysfunction⁹.

In this case, presence of diastolic dysfunction, cardiomegaly, biatrial dilatation and symmetrical biventricular hypertrophy suggest clinical overlap between the two phenotypes RCM and HCM. In some families, distinct HCM and RCM phenotypes segregate with the same disease causing sarcomeric mutation¹⁰.

Interestingly, children with mixed phenotype frequently (25%) have a family history of pure or mixed phenotype¹¹. However, in our case the family history was negative. Mixed phenotype of RCM/HCM has shown significant transplant free survival compared

to pure RCM¹¹. However, the survival is independent of the phenotype and further genetic and clinical exploration is needed to recognize genotype-phenotype correlations¹².

Complications such as pulmonary hypertension, embolic events, heart failure, arrhythmias or sudden death develops if cardiac transplantation is not performed. Increase proBNP level and systemic venous congestion suggest heart failure in this case. The mechanism of sudden death in RCM is unclear and is hypothesized that patients with ongoing myocardial ischemia are at a higher risk⁷.

Though most of the cases of paediatric cardiomyopathies are idiopathic (60-70%)¹³, familial, syndromic, metabolic and neuromuscular aetiologies are identified⁷ with many complex processes¹⁴. In this case, history and investigations are not suggestive of haemochromatosis, glycogen storage disorder, Fabry disease or irradiation. The histology revealed no amyloid, iron or metastatic tumour deposition or sarcoid granulomas.

There was no peripheral eosinophilia or eosinophilic infiltrate in other organs to suggest Loeffler endocarditis. Before concluding that this is a case of idiopathic cardiomyopathy we need to exclude the possibility of genetic mutations which we are unable due to lack of facilities. Future research is needed to understand how mutations in the same gene can cause distinct phenotypes which is important in medical management and screening the family members.

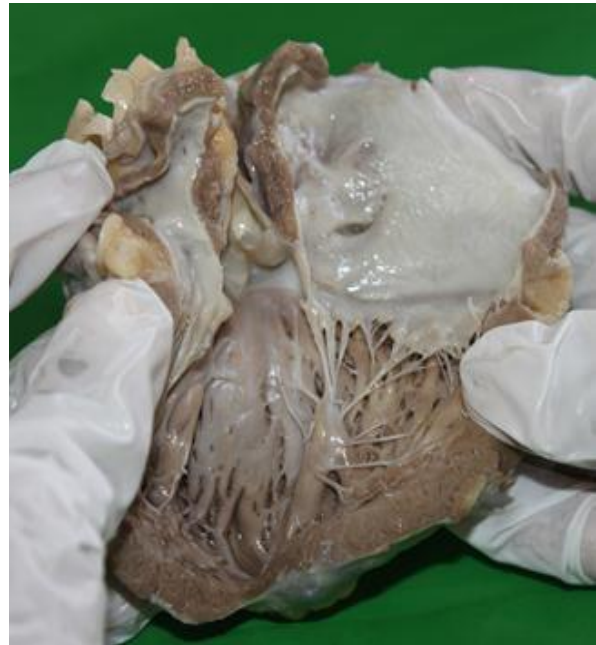

Figure 1: The cut opened heart displaying dilated atria, thickened ventricular wall, subendocardial fibrosis and shortened chordae

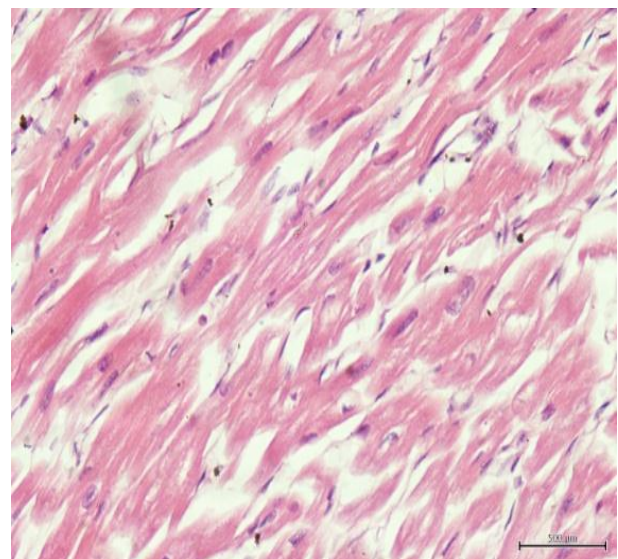


Figure 2 :Myofiber hypertrophy and disarray (H & E 40x10)

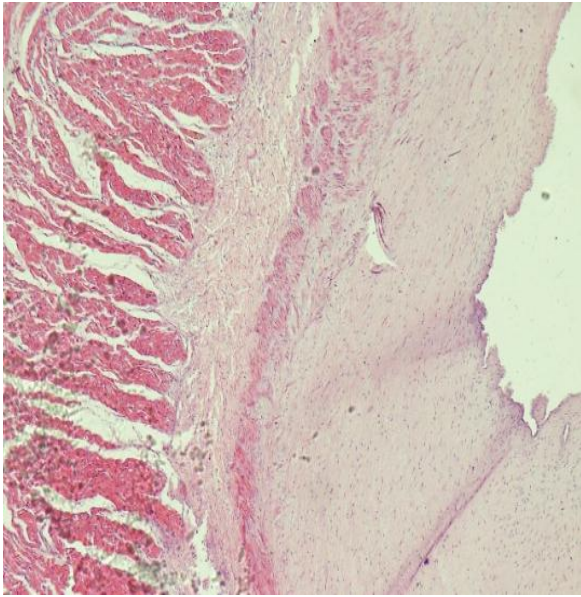


Figure 3: The left ventricle displaying marked subendocardial fibrosis and hypertrophy of myocytes. (H & E 4x10)

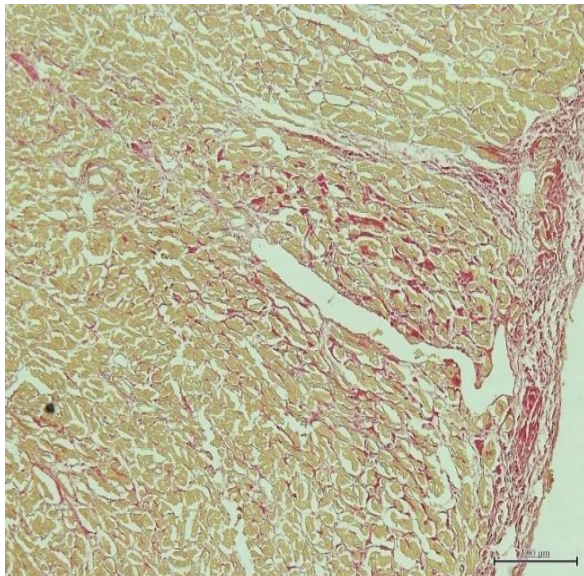


Figure 4: Subendocardial and interstitial fibrosis (Van Gieson stain 4x10)

CONCLUSION

1. RCM is a rare form of cardiac disease with an extremely poor outlook in children. This patient had classic functional and structural features of RCM together with increased biventricular wall thickness, which is an overlapping feature with HCM. Relatively less symptoms and longer survival in this child may be explained by mixed RCM/HCM phenotype.

REFERENCES

1. Petros Nihoyannopoulos, David Dawson. Restrictive cardiomyopathies, European Heart Journal - Cardiovascular Imaging, November 2009, Volume 10, Issue 8, DOI: <http://dx.doi.org/10.1093/ejehocard/jep156iii23-iii33>.
2. Steven E Lipshultz, Thomas R Cochran, Pediatric cardiomyopathies: causes, epidemiology, clinical course, preventive strategies and therapies [Future Cardiology](http://dx.doi.org/10.2217/fca.13.66). Nov 2013; 9(6): 817-848. doi: [10.2217/fca.13.66](http://dx.doi.org/10.2217/fca.13.66).
3. McKennaWJ, Report of the 1995 World Health Organization/International Society and Federation of Cardiology Task Force on the Definition and Classification of Cardiomyopathies, *Circulation*. 1996; 93: 841-842 doi: [10.1161/01.CIR.93.5.841](http://dx.doi.org/10.1161/01.CIR.93.5.841).
4. Denfield SW, Rosenthal G, Gajarski RJ, Bricker JT, Schowengerdt KO, Price JK, Towbin JA. Restrictive cardiomyopathies in childhood. Etiologies and natural history. *Tex Heart Inst J* 1997; 24: 38-44 [PMID: 9068138].
5. Susan W Denfield, Steven A. Webber, Restrictive Cardiomyopathy in Childhood, *October 2010* Volume 6, Issue 4, Pages 445-452, DOI: <http://dx.doi.org/10.1016/j.hfc.2010.05.005>.
6. Towbin JA, Bowles NE. The failing heart, *Nature* 2002; 415: 227-233 [PMID: 11805847 DOI: [10.1038/415227a](http://dx.doi.org/10.1038/415227a)].

10. Lipshultz SE, Sleeper LA, Towbin JA, Lowe AM, Orav EJ, Cox GF, Lurie PR, McCoy KL, McDonald MA, Messere JE, Colan SD. The incidence of pediatric cardiomyopathy in two regions of the United States. *N Engl J Med* 2003; 348: 1647-1655 [PMID: 12711739 DOI: 10.1056/NEJMoa021715].
11. Gewillig M, Mertens L, Moerman P, Dumoulin M. Idiopathic restrictive cardiomyopathy in childhood, *European Heart Journal*, Vol. 17, issue 9, pp 1413-1429.
12. T, Narita T, Sumino S. Hypertrophic cardiomyopathy without asymmetric hypertrophy, *British Heart Journal*. May 1982; 47(5): 507-510.
13. Mogensen J, Kubo T, Duque M, Uribe W, Shaw A, Murphy R, Gimeno JR, Elliott P, McKenna WJ. Idiopathic restrictive cardiomyopathy is part of the clinical expression of cardiac troponin I mutations. *Journal of Clinical Investigation* 2003; 111: 209-216 [PMID: 12531876 DOI: 10.1172/JCI16336].
14. Webber A, Steven E. Lipshultz et al. Outcomes of Restrictive Cardiomyopathy in Childhood and the Influence of Phenotype A Report From the Pediatric Cardiomyopathy Registry, *Circulation*, September 4, 2012 ;126:1237-1244.
15. Muhammad Tariq, Stephanie M. Importance of genetic evaluation and testing in pediatric cardiomyopathy, *World Journal of Cardiology*, 2014 November 26; 6(11): 1156-1165.
16. Pierre-Yves Jean-Charles, Yue-Jin Li, Chang-Long Nan, and Xu-Pei Huang.
17. Monitoring Editor: Prof Yong-Fu Xiao. Insights into restrictive cardiomyopathy from clinical and animal studies *J Geriatric Cardiology*. 2011 Sep; 8(3): 168-183.
18. Franz WM, Müller OJ, Katus HA. Cardiomyopathies: from genetics to the prospect of treatment. *Lancet*. 2001;358:1627-1637.

ESTIMATION OF STATURE FROM FOOT OUTLINE IN ADULT MALAYSIAN MALAYALEE ETHNICS FOR FORENSIC INVESTIGATION

T. Nataraja Moorthy¹ & Rasvini Asogan²

¹ Associate Professor of Forensic Sciences, Management and Science
University, Shah Alam, Selangor, Malaysia.

²Forensic Science Program, Management and Science University,
Shah Alam, Selangor

ABSTRACT

Identification is a key component in any forensic investigation. Estimation of stature is an identifying characteristics to solve the crime. Foot impression is known to be a valuable scientific evidence encountered in the scenes of crime. Examination of footprint helps in estimation of stature of an individual since there is a strong relationship exists between foot impression and stature. There are people who still have the habit of walking barefoot in Asian countries like Malaysia, Sri Lanka, India, Thailand and Indonesia. The hard surfaces produce two-dimensional footprints while foot outline provides the size parameters of the fleshed bare foot and also represents the boundaries of the foot's impression in soft soil, mud, or any other substances that produces a three-dimensional foot impression. It is shown that very limited studies were conducted on stature estimation from foot outline measurements. It is important to note that racial and cultural aspects of foot morphology must be considered while conducting the foot impression study. Researchers have cautioned that regression equations derived to estimate stature from foot impression for a particular population is erroneous to apply for other populations. Thus the present investigation is aimed to derive linear regression equations to estimate stature from foot outlines of Malaysian Malayalee ethnics.

Key words: Forensic Science, Forensic anthropology, Stature estimation, Foot outline, Malaysian Malayalee ethnics

Corresponding author:
natrajamoorthy@rediffmail.com

INTRODUCTION

The anthropometry-based Bertillon system was invented by French anthropologist Alphonse Bertillon for the purpose of human identification¹. Stature can be estimated using various body parts since there is a strong relationship exists between each part of the body and whole body²⁻⁶. Nothing exemplifies this truth more than the relationship that various parts of the body have to the stature of an individual⁷. In this way, an individual's foot impression may represent his or her identity. There are people who still have the habit of walking barefoot in Asian countries like Malaysia, Sri Lanka, India, Thailand and Indonesia⁸. Foot impressions are still found at crime scenes, since offenders often tend to remove their footwear either to avoid noise or to gain better grip in climbing walls, etc., while entering or exiting⁹. The foot impressions with characteristic features can provide valuable information even from partial foot impressions (2D & 3D) during crime scene investigation¹⁰. Stature can be estimated from anthropometric measurements of foot¹¹⁻¹⁶, footprint¹⁷⁻²¹ and foot outline²²⁻²⁵

because correlation exists between stature and foot/footprint/foot outline. The hard surfaces produce two-dimensional (2D) footprints while foot outline provides the size parameters of the fleshed bare foot and also represents the boundaries of the foot's impression in soft soil, mud, or any other substances that produces a three-dimensional (3D) footprint impression²⁶. Earlier foot/footprint/foot outline studies have been conducted on mixed populations. Researchers have cautioned that regression equations derived to estimate stature from foot impression for a particular population is erroneous to apply for other populations⁹⁻¹⁰. Hence, the present study is aimed to derive population specific regression equations to estimate stature from foot outline measurements of Malaysian Malayalee ethnics.

MATERIALS AND METHODS

Research location

The research location is Peninsular Malaysia, wherein most of the Malayalee are living. The Malaysian Malayalees have ancestral origins in the modern day state of Kerala, on south west coast of India with their mother tongue Malayalam. Although there are more than thirty-five million Malayalam language speakers in India, there are about 135,000 Malayalees are living in Malaysia. They have an association in Malaysia named as "All Malaysia Malayalee Association" or abbreviated as AMMA.

Sample collection

Based on the population, the study involved 110 adult Malaysian Malayalees (50 males, 60 females) of age ranged from 18 to 56 years. Subjects with any apparent foot-related disease, orthopaedic deformity, injury and age below 18 years were excluded from the study. Informed consent and ethical approval were obtained before sample collection. Stature measurements and foot outlines were recorded following the procedure adopted by Nataraja Moorthy²³⁻²⁵. Stature of each subject

was measured using a portable body meter measuring device (SECA model 206).

The height of the subjects was measured at a fixed time in the evening because of diurnal variation in stature. After cleaning the feet of the subjects, the left foot was requested to place on an A4 size white paper and the foot outline was drawn with a sharp-pointed pencil and the anatomical landmarks of the foot, namely mid-rear heel point (pternion,P) in the base line and most anterior points of all toes (LT1-LT5) were marked (Figure 1). The procedure was repeated for the right foot and for other subjects. All foot outline samples and information relating to participants were coded with sample ID for anonymity.

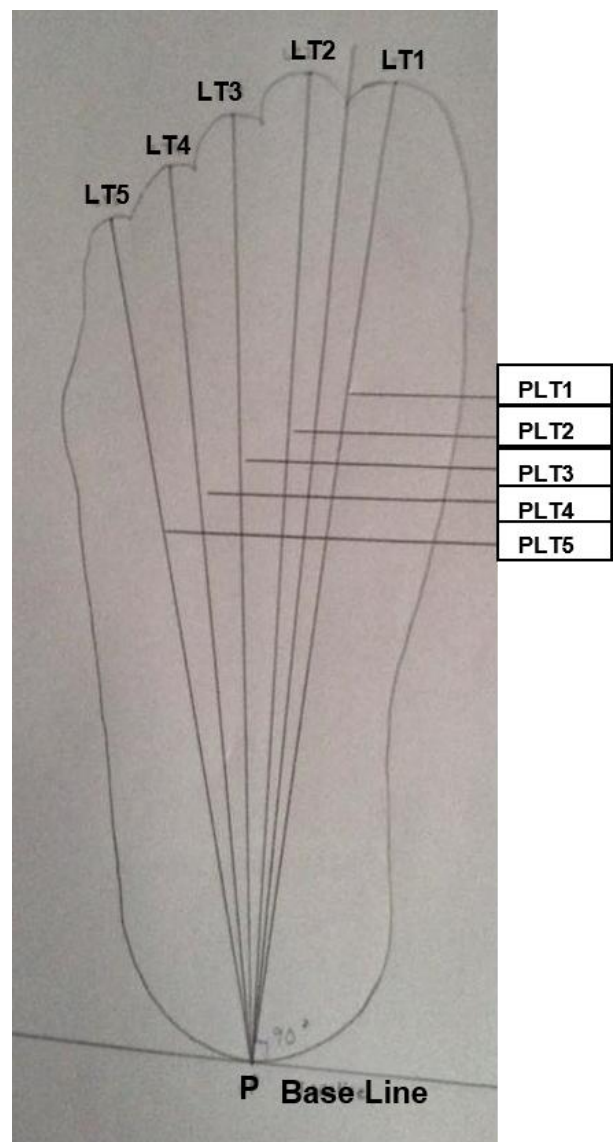


Figure 1: Landmarks and diagonal length measurements on left foot outline

Statistical analysis

The data were analyzed using SPSS software version 21. Bilateral asymmetry was calculated for each of the foot outline measurements and tested for significance using one sample t-test. Pearson’s correlation coefficients (R) between various feet outline lengths and stature were obtained. The linear regression analysis method was employed to derive regression equations for stature estimation from various foot outline lengths since stature estimation from foot outline length is more accurate and reliable with regression analysis²⁷. The standard error of estimation (SEE) was calculated to analyze the deviation of the estimated stature from the actual stature for foot outline measurements.

RESULTS

All foot outline measurements exhibit statistically positive significant correlation with stature. Table-1 shows the descriptive statistics of stature measurements in males, females and pooled sample. In males, the stature ranges from 154.0 to 182.0 cm (mean 167.9cm) and in females, it ranges from 139.0 to 167.0 cm (mean 153.1 cm). In pooled sample, the stature ranges from 139.0 to 182.0 cm (mean 159.7). The results showed that mean stature is found to be significantly higher in males than females.

Table 1: Descriptive statistics of stature in males, females and pooled sample of adult Malaysian Malayalees (in centimeters).

	Min	Max	Mean	RD	SD
Male (N=50)	154.00	182.0	167.9	28.0	7.2
Female (N=60)	139.0	167.0	153.1	28.0	6.9
Pooled sample (N=110)	139.0	182.0	159.7	43.0	10.2

SD: standard deviation; RD: range difference; Min: minimum; Max: maximum; Table 2 to 4 present the descriptive statistics of various foot outline lengths i.e. diagonal length between the rear heel end (P) and anterior points of each toe in both left (LT1-LT5) and right (RT1-RT5) of males, females and pooled sample. All the foot outline length measurements in males are found to be larger than females both in left and right feet.

Table 2: Descriptive statistics of foot outline length measurements in males in adult Malaysian Malayalees (in centimeters). N=50

Variables	Min	Max	Mean	RD	SD
PLT1	22.1	28.5	25.80	6.4	1.4
PLT2	21.6	27.8	25.27	6.2	1.4
PLT3	21.0	26.8	24.47	5.8	1.3
PLT4	20.0	25.1	23.18	5.1	1.2
PLT5	18.6	23.8	21.51	5.2	1.2
PRT1	22.1	28.1	25.54	6.0	1.4
PRT2	21.7	27.6	25.16	5.9	1.2
PRT3	21.2	26.8	24.46	5.6	1.2
PRT4	20.5	25.0	23.18	4.5	1.1
PRT5	19.1	23.8	21.59	4.7	1.0

Min: minimum; Max: maximum; PLT1 to PLT5: left lengths from anterior part of toes outlines LT1- LT5 to outline mid-rear outline heel point P; PRT1 to PRT5: right lengths from anterior part of toes outline RT1-RT5 to mid-rear outline heel point P; RD: range difference; SD: standard deviation; N : number of samples.

Table 3: Descriptive statistics of foot outline length measurements in females in adult Malaysian Malayalees (in centimeters). N=60

Variables	Min	Max	Mean	RD	SD
PLT1	20.5	26.0	23.55	5.5	1.3
PLT2	20.4	25.4	23.02	5.0	1.3
PLT3	19.7	24.7	22.17	5.0	1.3
PLT4	18.3	23.7	20.99	5.4	1.2
PLT5	17.4	22.0	19.54	4.6	1.1
PRT1	21.1	25.5	23.47	4.4	1.2
PRT2	20.8	25.2	23.05	4.4	1.1
PRT3	20.1	24.7	22.30	4.6	1.1
PRT4	19.2	23.6	21.17	4.4	1.1
PRT5	18.3	21.7	19.73	3.4	0.9

Min: minimum; Max: maximum; PLT1 to PLT5: left lengths from anterior part of toes outlines LT1- LT5 to outline mid-rear outline heel point P; PRT1 to PRT5: right lengths from anterior part of toes outline RT1-RT5 to mid-rear outline heel point P; RD: range difference; SD: standard deviation; N : number of samples.

Table 4: Descriptive statistics of foot outline length measurements in pooled sample in adult Malaysian Malayalees (in centimeters). N=110

Variables	Min	Max	Mean	RD	SD
PLT1	20.5	28.5	24.57	8.0	1.8
PLT2	20.4	27.8	24.04	7.4	1.7
PLT3	19.7	26.8	23.22	7.1	1.7
PLT4	18.3	25.1	21.99	6.8	1.6
PLT5	17.4	23.8	20.44	6.4	1.5
PRT1	21.1	28.1	24.41	7.0	1.6
PRT2	20.8	27.6	24.01	6.8	1.6
PRT3	20.1	26.8	23.29	6.7	1.6
PRT4	19.2	25.0	22.08	5.8	1.5
PRT5	18.3	23.8	20.57	5.5	1.4

Min: minimum; Max: maximum; PLT1 to PLT5: left lengths from anterior part of toes outlines LT1- LT5 to outline mid-rear outline heel point P; PRT1 to PRT5: right lengths from anterior part of toes outline RT1-RT5 to mid-rear outline heel point P; RD: range difference; SD: standard deviation; N : number of samples.

A salient feature observed in the foot outline lengths is that the first toe-heel foot outline length in both left and right are found to be the longest in males and females in both genders. The left foot outline lengths are found to be larger than the right in both males and females showing the existence of bilateral asymmetry.

Table 5-7 depict the linear regression equations for stature estimation in adult males, females and the pooled sample through various foot outline length measurements and ANOVA.

Table 5: Linear regression equations for stature estimation through various foot outline length measurements and ANOVA in adult male Malaysian Malayalees (in centimeters). N=50

Variables	Regression Equations	SEE	R	R ²	Coefficient of t-test	ANOVA
PLT1	56.731 + 4.310PLT1	3.792	0.86	0.732	11.436	130.791(1,48);p<0.001
PLT2	60.116 + 4.267PLT2	4.362	0.80	0.645	9.334	87.129 (1,48);p<0.001
PLT3	59.598 + 4.427PLT3	4.495	0.79	0.623	8.901	79.232 (1,48);p<0.001
PLT4	60.249 + 4.647PLT4	4.589	0.78	0.607	8.607	74.081 (1,48);p<0.001
PLT5	66.924 + 4.696PLT5	4.860	0.75	0.559	7.801	60.853 (1,48);p<0.001
PRT1	59.707 + 4.237PRT1	4.404	0.80	0.638	9.195	84.556 (1,48);p<0.001
PRT2	57.332 + 4.396PRT2	4.783	0.76	0.573	8.025	64.394(1,48);p<0.001
PRT3	58.276 + 4.483PRT3	4.819	0.75	0.566	7.917	62.683 (1,48);p<0.001
PRT4	59.513 + 4.678PRT4	5.011	0.73	0.531	7.375	54.393 (1,48);p<0.001
PRT5	59.818 + 5.008PRT5	5.127	0.71	0.509	7.056	49.783 (1,48);p<0.001

PLT1 to PLT5: left lengths from anterior part of toes outline LT1- LT5 to outline mid-rear heel point P; PRT1 to PRT5: right lengths from anterior part of toes outline RT1-RT5 to outline mid-rear heel point P; SEE: standard error of estimate; R: Correlation coefficient; R²: coefficient of determination. p-value < 0.001 is significant

Table 6: Linear regression equations for stature estimation through various foot outline length measurements and ANOVA in adult female Malaysian Malayalees (in centimeters). N=60

Variables	Regression Equations	SEE	R	R ²	Coefficient of t-test	ANOVA
PLT1	68.600 + 3.590PLT1	5.053	0.68	0.468	7.140	50.980 (1,58);p<0.001
PLT2	68.827 + 3.662PLT2	5.103	0.68	0.457	6.992	48.885 (1,58);p<0.001
PLT3	77.127 + 3.428PLT3	5.228	0.66	0.430	6.618	43.804 (1,58);p<0.001
PLT4	74.370 + 3.752PLT4	5.105	0.68	0.457	6.984	48.780 (1,58);p<0.001
PLT5	63.983 + 4.562PLT5	4.882	0.71	0.503	7.666	58.765 (1,58);p<0.001
PRT1	60.438 + 3.950PRT1	5.178	0.66	0.441	6.766	45.776 (1,58);p<0.001
PRT2	57.231 + 4.161PRT2	4.992	0.69	0.481	7.327	53.691 (1,58);p<0.001
PRT3	61.899 + 4.091PRT3	5.111	0.68	0.456	6.966	48.526 (1,58);p<0.001
PRT4	60.150 + 4.392PRT4	4.929	0.70	0.494	7.521	56.567 (1,58);p<0.001
PRT5	51.776 + 5.139PRT5	4.952	0.70	0.489	7.449	55.489 (1,58);p<0.001

PLT1 to PLT5: left lengths from anterior part of toes outline LT1- LT5 to outline mid-rear heel point P; PRT1 to PRT5: right lengths from anterior part of toes outline RT1-RT5 to outline mid-rear heel point P; SEE: standard error of estimate; R: Correlation coefficient; R²: coefficient of determination. p-value < 0.001 is significant

Table 7: Linear regression equations for stature estimation through various foot outline lengths measurements and ANOVA in pooled samples in Malaysian Malayalees (in centimeters). N=110

Variables	Regression Equations	SEE	R	R ²	Coefficient of t-test	ANOVA
PLT1	36.625PLT1 + 5.016	5.057	0.87	0.756	18.307	335.157 (1,108);p<0.001
PLT2	37.858PLT2 + 5.074	5.256	0.86	0.737	17.386	302.259 (1,108);p<0.001
PLT3	43.716PLT3 + 5.002	5.387	0.85	0.723	16.810	282.565 (1,108);p<0.001
PLT4	42.909PLT4 + 5.320	5.319	0.86	0.730	17.104	292.554 (1,108);p<0.001
PLT5	39.071PLT5 + 5.911	5.277	0.86	0.735	17.292	299.012 (1,108);p<0.001
PRT1	29.483PRT1 + 5.341	5.380	0.85	0.724	16.840	283.602 (1,108);p<0.001
PRT2	28.221PRT2 + 5.483	5.313	0.86	0.731	17.131	293.471 (1,108);p<0.001
PRT3	32.526PRT3 + 5,469	5.346	0.85	0.728	16.986	288.517 (1,108);p<0.001
PRT4	31.532PRT4 + 5.811	5.363	0.85	0.726	16.913	286.050V(1,108);p<0.001
PRT5	27.382PRT5 + 6.439	5.349	0.85	0.727	16.974	288.117 (1,108);p<0.001

PLT1 to PLT5: left lengths from anterior part of toes outline LT1- LT5 to outline mid-rear heel point P; PRT1 to PRT5: right lengths from anterior part of toes outline RT1-RT5 to outline mid-rear heel point P; SEE: standard error of estimate; R: Correlation coefficient; R²: coefficient of determination.
p-value < 0.001 is significant

Correlation coefficient (R) values are found to be higher in the pooled sample (0.85–0.87) when compared with males (0.71–0.86) and females (0.66–0.71) separately. The coefficient of determination (R²), the predictive accuracy, is found to be higher in the pooled sample (0.723-0.756) when compared with males (0.509-0.732) and females (0.430-0.494) and all measurements are found to be positive and statistically significant (<0.001) for stature estimation.

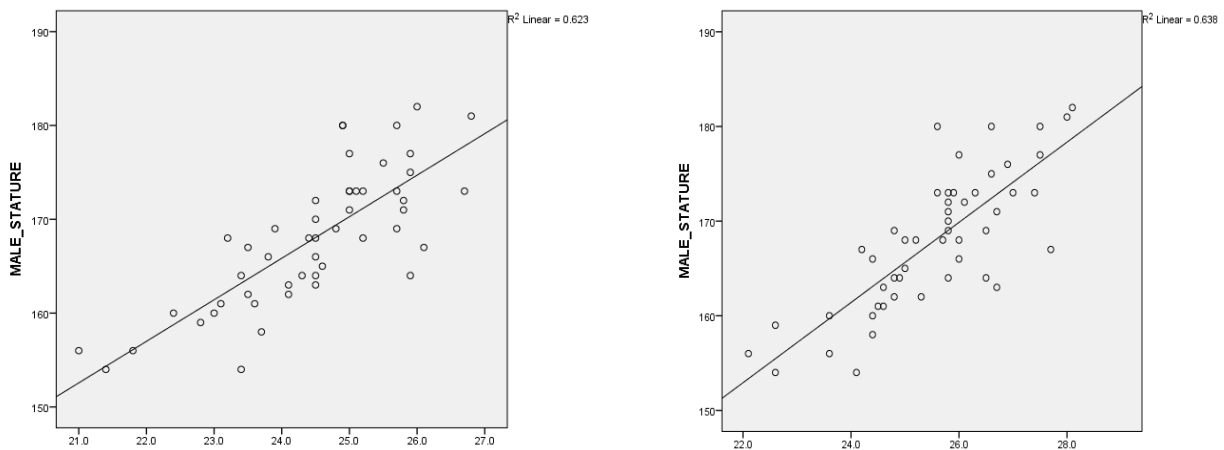


Figure 2: Illustrative examples of scatter graphs showing the relationship between foot outline lengths (left and right) and stature in adult male Malaysian Malayalees.

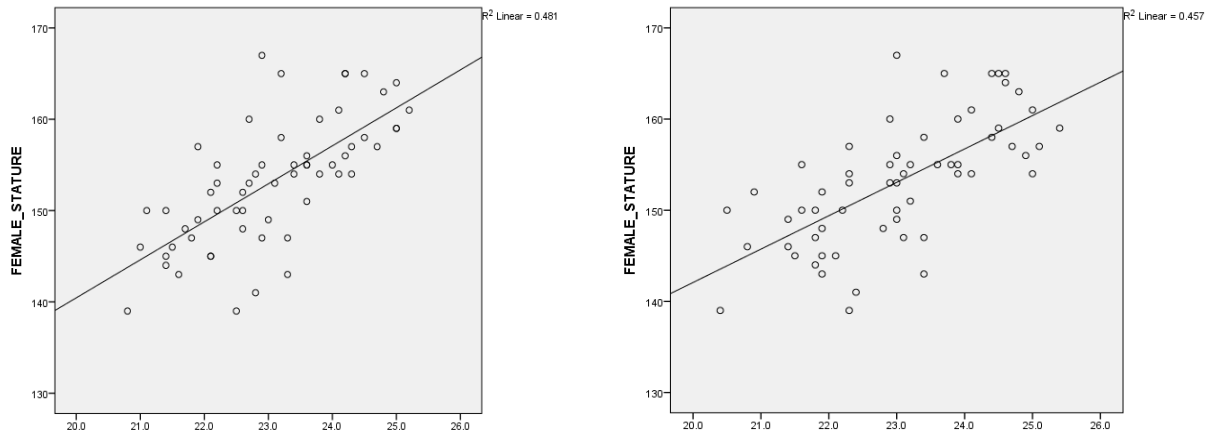


Figure 3: Illustrative examples of scatter graphs showing the relationship between foot outline lengths (left and right) and stature in adult female Malaysian Malayalees.

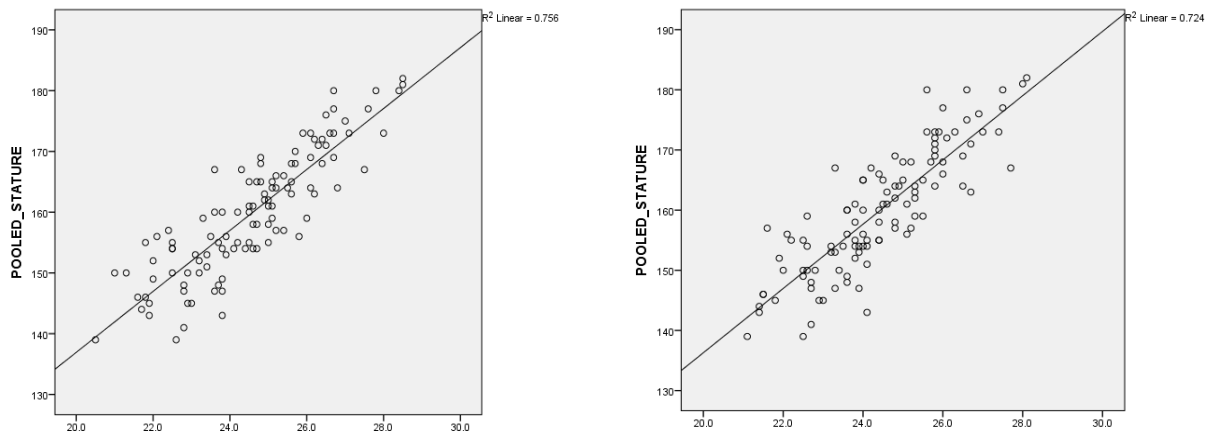


Figure 4: Illustrative examples of scatter graphs showing the relationship between foot outline lengths (left and right) and stature in pooled samples of Malaysian Malayalees.

A few illustrative examples of graphs with fitted lines for foot outline and stature in males (Figure 2), females (Figure 3) and the pooled sample (Figure 4) are presented. All graphs show positive correlation between stature and foot outline length measurements.

DISCUSSION

Stature is found to be larger in males than females, showing the existence of a statistically significant gender difference in Malaysian Malayalees. This may be attributed general male-female differences and natural size in both sexes. This finding is in accordance with the previous studies²²⁻²⁸. The foot outline provided the size parameters of the fleshed bare foot and also represents the boundaries of the foot's impression in soft soil surfaces that produces a 3D footprint impression. The investigation revealed that the left foot outline measurements are found to be larger in both sexes and hence the existence of left-sided asymmetry. Similar observations were noted in Malaysian Malays⁹, male Gujjars of North India¹⁰, male Egyptian¹⁷, Indian²⁹ and male Jat Sikh in North Indian³⁰. Researchers³¹ suggested that in majority of both left and right handed persons, the left foot is more used than the right.

The age of the subjects is above 18 years and considered appropriate since average length of the adult's foot is attained by the age of 16 years in male and 14 years in females³². The researchers concluded that to estimate stature, irrespective of ethnics, toe-to-heel length measurements are more reliable and accurate than from any other measurements such as breadth measurements etc.^{9-10, 21-22}. The result of the study indicated that the correlation coefficient (R) between stature and foot outline length measurements is higher in pooled sample compared to male and female individually. Hence the regression equations derived for pooled samples can be used to estimate stature since the sex of the 3D foot impression is unknown in real crime scenes. The standard error of estimate (SEE) is a measure of accuracy of predictions. Researchers shown that regression equations can be derived for stature estimation using foot and hand measurements with a great accuracy in both males and females show high reliability and accuracy with low SEE. The SEE values are found to be low in the present study.

CONCLUSION

The result of this research provided linear regression equations for stature estimation from foot outline (3D foot impression) anthropometry in Malaysian Malayalee ethnics. The findings of the study will be applicable to complete and even partial foot impressions found in soft soil or mud. The research shows that the regression equation without gender indicators perform significantly better than do models with sex indications, as in real crime scenarios.

CONFLICT OF INTEREST

The authors have no conflict of interest to declare.

ACKNOWLEDGMENT

The authors are thankful to all participants who took part in this strenuous study. Authors are grateful to Management and Science University for encouraging research and its publication in international journals.

REFERENCES

1. Kennedy KAR. Forensic anthropology in the USA. In: Siegel J, Knupfer G, Saukko P, editors. Encyclopedia of forensic sciences. London (SanDiego): Academic Press; 2000. pp. 1059-1064.
2. Ozaslan A, Iscan MY, Ozaslan I, Tugcu H, Koc S. Estimation of stature from body parts. *Forensic Science International*. 2003; **132** (1): 40-45.
3. Zverev YP. Relationship between arm span and stature in Malawian adults. *Annals of Human Biology*. 2003; **30** (6):739-743.
4. Sanli SG, Kizilkanat ED, Boyan N, Ozsahin ET, Bozkir MG, Soakes R, Erol H, Oguz O. Stature estimation based on hand length and foot length. *Clinical Anatomy*. 2005; **18** (8): 589-596.
5. Mahakkanukrauh P, Khanpetch P, Prasitwattanseree S, Vichairat K, Troy Case D. Stature estimation from long bone length

- in a Thai population. *Forensic Science International*. 2011; **210**: 279 e1-7.
6. Pelin C, Duyar I, Kayahan EM, Zagyapan R, Agildere AM, Erar A. Body height estimation based on dimensions of sacral and coccygeal vertebrae. *Journal of Forensic Science*. 2005; **50** (2): 294-297.
 7. Philip TA. Formulae for establishing stature from foot size by regression method. *Journal of Indian Academy of Forensic Medicine*. 1990; **12**:57–62.
 8. Hairunnisa MAK and Nataraja Moorthy T. Stature estimation from the anthropometric measurements of foot outline in adult indigenous Melanau ethnics of east Malaysia by regression analysis. *Sri Lanka Journal of Forensic Medicine, Science & Law*. 2013;**4** (2):27–35.
 9. Nataraja Moorthy T, Mazidah K, Hadzri M, Jayaprakash PT. Estimation of stature based on foot length of Malays in Malaysia. *Australian Journal of Forensic Sciences* 2011;**43**:13–26.
 10. Krishan K. Individualizing characteristics of footprints in Gujjars of north India—forensic aspects. *Forensic Science International* 2007; **169**:137–144.
 11. Ilayperuma I, Nanayakkara BG, Palahepitiya KN. A model for reconstruction of personal stature based on the measurements of foot length. *Galle Medical Journal* 2008;**13**(1): 6-9
 12. Petra U, Radoslav B, Sona M. Stature estimation from various foot dimensions among Slovak population. *Journal of Forensic Sciences* 2013; **58**(2): 448-451.
 13. Mansur DI, Haque MK, Sharma K, Karki RK, Khanal K, Karna R. Estimation of Stature from foot length in adult Nepalese population and its clinical relevance. *Kathmandu University Medical Journal* 2012; **37**(1):16-9.
 14. Sonali K, Ashias A. Estimation of stature from the measurement of foot length, hand length and head length in Maharashtra region. *Indian Journal of Basic & Applied Medical Research* 2012; **1**(2): 77-85.
 15. Salina H, Mamat S, Che R, Ibrahim, Mohamad A. Regression analysis for stature estimation from foot anthropometry in Malaysian Chinese. *Australian Journal of Forensic Sciences* 2012; **44** (4): 333-341.
 16. Pradeep KP, Abhilasha D. Study of correlation between human height and foot length in residents of Mumbai. *International Journal of biological and medical research* 2012; **3**(3): 2072 -2075.
 17. Irene Atef Fawzy,1 M.D. and Nashwa Nabil Kamal,2 M.D. Stature and Body Weight Estimation from various footprint measurements among Egyptian population. *Journal of Forensic Sciences* 2010; **55**(4): 884-888
 18. Reel S, Rouse S, Vernon W, Doherty D. Estimation of stature from static and dynamic footprints. *Forensic Science International* 2012; **219**: 283.e1–283.e5.
 19. Naomi H, Ambika F, Nur-Intaniah I, Daniel F, Tytuł A. Estimation of stature using anthropometry of feet and footprints in a Western Australian population. *Journal of Forensic and Legal Medicine* 2013; **20**(5): 435-441.
 20. Nataraja Moorthy T, Nurul A, Hairun Nisa M. Stature estimation based on footprint measurements of Malays in Peninsula Malaysia by regression analysis. *International Journal of biomedical and advance research* 2013; **4**(10):683-689.
 21. Nataraja Moorthy T, Mustaqqim A, Boominathan R, Raman N. Stature estimation from footprint measurements in Indian Tamils by regression analysis. *Egyptian Journal of Forensic Sciences*. 2014; **4**:7-16.
 22. Hairunnisa MAK and Nataraja Moorthy T. Stature estimation from foot outline measurements in adult Bidayuhs of east Malaysia by regression analysis. *Indonesian Journal of legal and forensic sciences*. 2013;**3** (1); 6-10.
 23. Hairunnisa MAK and Nataraja Moorthy T. Estimation of stature from foot outline measurements in Ibans of east Malaysia by regression analysis. *International journal of biomedical and advance research*. 2013;**4** (12); 889-895.
 24. Nataraja Moorthy T, Ang YL, Saufee AS and Nik Fakhruddin NH. Estimation of stature from footprint and foot outline measurements

- in Malaysian Chinese. *Australian Journal of Forensic Sciences*. 2014;**46** (2); 136-159.
25. Robbins LM. Estimating height and weight from size of footprints. *Journal of Forensic Sciences* 1986; **31**:143–52.
26. Krishan K, Kanchan T, Sharma A. Multiplication factor versus regression analysis in stature estimation from hand and foot dimensions. *Journal of Forensic and Legal Medicine* 2012; **19**:211–214.
27. Gulsah Z, Ipek E, Zehra D. Stature and gender estimation using foot measurements. *Forensic Science International*. 2008;**181**:54e1–54e5.
28. Tanuj K, Ritesh G, Rohan M, Ramneet K, Kotian MS, Rakesh K. Stature estimation from foot length using universal regression formula in a north Indian population. *Journal of Forensic Science*. 2010;**55**:163–166.
29. Tanuj K, Krishan K, Shyamsundar S, Aparna KR, Sankalp J. Analysis of footprint and its parts for stature estimation in Indian population. *The foot*. 2012;**22**:175–180.
30. Jasuja OP, Singh J, Manjari J. Estimation of stature from foot and shoe measurements by multiplication factors: a revised attempt. *Forensic Sci Int*. 1991;**50**:203–215.
31. Chhibber SR, Singh I. Asymmetry in muscle weight and one-sided dominance in the human lower limbs. *Journal of Anatomy*. 1970;**106**:553–556.
32. Anderson M, Bias M, Green WT. Growth of the normal foot during childhood and adolescence- length of the foot and interrelations of foot, stature and lower extremity as seen in serial records of children between 1–18 years of age. *Am J Phys Anthropol*. 1956;**14**:287– 308.

A DERMATOLOGICAL INDUCED ATTEMPT BY A HUSBAND TO MAKE HIS ESTRANGED WIFE LEAVE HOME

Jayasooriya, R. P.¹, Sivasubramaniam M.², Chandrakirthi, W. A. N.²

¹Dept. of Forensic Medicine, Faculty of Medicine, University of Peradeniya, Sri Lanka

²J.M.O's Office, Teaching Hospital, Kandy, Sri Lanka

ABSTRACT

This case report presents a case of domestic violence using an unusual approach to compel the wife to leave home in an attempt to continue an extramarital affair. The method used by the husband in this case is a herbal plant known as *Dendrocnide sinuate* or commonly known in Sri Lanka as 'gas kahambiliya' or 'Ma Ussa' which causes a severe dermatological reaction.

Key words: Domestic violence, *Dendrocnide sinuate* Ma Ussa

Corresponding author:
rpjayasooriya@gmail.com

INTRODUCTION

Wife battering prevails not only in Sri Lanka but also worldwide. One in three women across the globe is physically or sexually abused during her lifetime, and many of them at the hands of the husband or intimate partner.¹ This case report discusses an unusual technique allegedly used by a husband to chase away his wife from his home. Thus, dried leaves of the 'MA-USSA' plant (*Dendrocnide sinuate*) that has potentially hyper-responsive dermatological and respiratory reaction were powdered and sprinkled on the wife's clothes and bed sheets to cause flare up of macula-papule eruptions on contact with skin.

Clinical History

A 33 year old married lady experienced urticaria rash after bathing and changing in to new clothes. She was repeatedly admitted to the local hospital for treatment. The rash subsided in one or two days after hospitalization and recurred after discharge when she revisited her husband's house. An itching macula-papule rash on the face, arms and legs was observed. It mostly occurred with bouts of fever. As a result of frequent admission, she was transferred to a tertiary care teaching hospital for specialized dermatological attention. The diagnosis was contact dermatitis by an unspecified agent. At the last admission, the patient was referred to the Judicial Medical Officer (JMO) as she had informed the dermatologist that she was frequently assaulted by her husband for two years asking her for divorce because he was having another extramarital affair. She had a history of being admitted to the local hospital on several occasions as a result of assault. She had informed this to the relevant police station several times previously. The Judicial Medical Officer (JMO) had taken a detailed history upon which the Police had strongly advised her husband to stop assaulting her and that if she complains again, he would be produced before the court of law for the institution of legal proceedings. After the police intervened, she was not assaulted as previously but she has been suffering from this particular skin condition. Her husband had suggested that she leaves his home immediately to her parents' house as she was at the risk of an allergic attack if she

remained in his residence and that if otherwise this dermatitis rash would not be cured. When she refused his advice her dermatitis condition became worse and she had to be admitted to the local hospital. At the end of the history taking and examination, the JMO advised her to search her clothes as well as the house (even husband's cupboards) carefully for causative factors of this skin condition. Then she found some dried leafy vegetable matter in her husband's brief case and found some packets that contained powder like leaf dust in it. When she came into contact with this leaf, she developed the same skin rash. This was the cause for her skin dermatitis which her husband had caused by keeping this leaf powder among her clothes.

DISCUSSION

Violence against women is a problem not only in Sri Lanka but all over the world. It is said to be as old as the history of mankind¹. It is a common practice in the traditional male dominated societies and where females have to depend totally upon their husbands. Although statistic does not indicate, it is quite a common problem in Sri Lanka. Most cases of wife battering are underreported. The main reason for this may probably be social and cultural habits. Mostly, the reason for the violence in a family may be poverty, pervasive psychological abuse, alcoholism, emotional insecurity and border line personality disorders².

Wife battering is defined as deliberate and demonstrable physical injuries caused by the marital partner^{2,3}. But this is not clearly satisfactory because certain forms of violence such as shaking may not leave demonstrable physical injuries. Especially, in this case her husband used to spray some leaf particles on her clothes and bed sheets and then she developed severe skin itching and dermatitis rash. This is also very devious type of wife battering. Her husband has used this special method because the police have strongly advised him to refrain from physical violence. So he had then selected this method of

hurting her (battering) without making her sustains physical injuries.

There is a common misconception among general public of the safety of so called herbal products. One seems to conveniently forget the definitive fatalities with plant poisons *G. superba* (Niyangala), *S. nuxvomika*, etc., still commonly observed in rural medical institutions. Furthermore, general surgeons and dermatologists encounter hypersensitive reactions on a regular basis for 'paththu' and various 'herbal' applications that are used as remedies for various ailments.

The plant that is being discussed here was identified by a botanist as *Dendrocnide sinuata*. It is a major shrub species in tropical evergreen forests. This species is well known in many languages throughout Asia, In Sinhala as 'MA-USSA' or "GAS KAHABILIYA" In Tamil Yanai meratti which means threatens elephants stinging tree, said to be planted at edge of villages to keep the wild elephant's away⁵. In English, Devil Nettle, Fever Nettle or Elephant fever Nettle. (Meaning 'tree nettle' with 'wavy leaf margin' in Greek). It is found in the forests of the Western Ghats of India, Sri Lanka and the Northeast and onwards into Southeast Asia⁵.

Some of its uses in herbal medicine have been scientifically validated. Upon contact with skin the nettle causes a painful itch, hives, fever and chills, skin depressions and clamminess which can recur over 10 days to six months. It's not sure what toxin in the plant causes such severe reactions but formic acid, serotonin, histamine, oxalic acid and tartaric acid are some of the suspected ingredients. When the antidote lime juice or turmeric is smeared on the affected areas apparently the symptoms immediately subside.

The juice of the root is reported to be used in chronic fevers. The roots are also boiled in water and the decoction is given to cure jaundice. The roots and leaves are used to prepare poultice and applied to heal boils, carbuncles, wounds, burns and rashes. The root extract has strong antibacterial activity

against both Gram (+) and Gram (-) bacteria due to presence of 2a, 3, 21, 24, 28-pentahydroxy-olean-12-enes. *Dendrocnide sinuata* has been used as medicine for curing diverse ailments including fever, chronic fever, malaria, dysentery, urinary disorder, irregular menstruation, swelling, blind abscesses and hypersensitivity by most ethnic tribal communities of North East India⁵.

CONCLUSION

There is a rare method of spouse abuse by using dried biological product of *Dendrocnide sinuata* plant.



Sri Lankan” MA-USSA “plant

REFERENCES

1. Violence against women. An issue of Human Rights. Gend Action: 1997; 1(4).
2. Saravanapavananthan N, Medico-Legal Aspect of Injuries. Jaffna: St Joseph's Catholic Press. 1988.
3. Knight B. Forensic Pathology. 2nd Edition. 1996. Arnold, London.
4. I. K, Bengamin J S. Spouse Abuse Comprehensive Textbook of Psychiatry. 4th Edition. 1985. Vol, 1, p 1092-1093.
5. Indian Journal of Natural Products and Resources, Vol. 1(1), March 2010.pp.17-21.
6. Samarasekera A, Wife Battering and Some of its Social and Medico- legal Aspects. Paper Presentation at the Academic Sessions of the Sri Lanka Medical Council. 1988.
7. World Health Organization (WHO) Report on 'Traditional Medicine Strategy', 2002-2005.

FORENSIC ART: 2D FACIAL COMPOSITE THROUGH IMAGE PROCESSING TECHNIQUES IN SRI LANKA

Sivaneasharajah L.,¹ Perera M.A.S.,¹ Jayasekara P.B.,¹ Perera J.,² Karunaratne D.D.,¹ Sandaruwan K.D.,¹, Rajapakse R.N.¹

¹University of Colombo School of Computing

²Department of Forensic Medicine and Toxicology, Faculty of Medicine, University of Colombo, Sri Lanka

ABSTRACT

INTRODUCTION

Forensic art is a technique used by law enforcement in order to identify a suspect towards apprehension or conviction of wanted persons and composite art is one branch. A “facial composite” is a graphical representation of a human face according to eyewitnesses' description. The failure rate of suspect identification through manual facial composite sketch was reportedly quite high in 2014 in Sri Lanka¹. In addition, international software available for face identification may not be the best approach for Sri Lankan population.

OBJECTIVE

To develop an automated, image processing based computer software solution using 2D facial feature templates for suspect identification in Sri Lanka.

STUDY DESIGN

Facial feature templates were constructed by analyzing a dataset from Sri Lankan young adult population focusing on most occurring facial indices and commonly available facial feature shapes. Anthropometric proportion indices measurements and shape classification for eyes, nose, face, upper vermilion and lower vermilion of 140 undergraduates of both sexes between 20-25 age were identified and categorized according to BMI (Body Mass Index). Face Software

Development Kit library (Face SDK library) was used for index measurements and domain expert knowledge from aesthetic and forensic art fields were utilized in identifying facial feature shapes. These parameters were incorporated to construct 2D facial feature templates for major facial feature. Then these templates were transferred into the system to be used for composite construction purpose. Finally face visualization process will perform iteratively until the eyewitness is satisfied with the ultimate image. Evaluation of this solution with face pool technique and anthropometric index evaluation techniques obtained 70.19% accuracy and average of 84% respectively.

CONCLUSION

A significant accuracy level in composite images has been obtained by using anthropometric indices measurements. Hence, this computerized solution will significantly enhance the currently used manual facial composite procedure for suspect identification in Sri Lanka ensuring justice to the victim of crime.

Key words: *Facial composite, anthropometric measurements, Facial indexes, Facial feature templates, Sri Lankan*

Corresponding author:
pererajejan32@yahoo.com

A “facial composite” is a graphical representation of a human face according to the eyewitnesses' description. In Sri Lanka forensic art for purposes of suspect identification is through manual hand drawing to obtain a facial composite. However, the failure rate of suspect identification through manual facial composite sketch was reportedly quite high in 2014 in Sri Lanka¹. However, the failure rate of suspect identification through this manual facial composite sketch has been declared as 92.86% in the year 2014 in Sri Lanka¹. This higher failure rate emphasizes the necessity of an immediate solution for the facial composite. It is also important to realize that incapability of identifying perpetrators of crime may leave the country in a precarious position as there is a seemingly rising number of crimes in the country. In order to overcome this situation, an automated, image processing based computer software solution has been introduced with 2D facial feature templates by incorporating both medically defined indices and aesthetic aspects⁵.

Even though there are numerous international software², these software are not the best suited to be adopted to Sri Lankan context as the facial feature templates which are available in these software may not be relevant for Sri Lankan population¹.

Since Sri Lanka is at its infancy level in facial composite this research attempts to bridge the gap in order to find out the optimum way to automate this traditional procedure by incorporating the information technologies (image processing) and statistical analysis techniques and its related aspects. Thus as a first step, facial feature templates need to be constructed by analyzing a dataset from Sri Lankan population.

In early studies it was proven that the ability of assessing facial feature appearance has been achieved by anthropometric proportion indices and this has been used for a number of forensic practices³. Hence, when constructing the facial feature templates this research focused on two major parameters known as most occurring indices and commonly available facial feature shapes. In order to find the relative measurements for these parameters, two sub researches on facial anthropometric indices and shape classification were carried out targeting the local population. Therefore in the first phase of the research, aforementioned sub researches were conducted with 140 undergraduate students (both male and female) who are aged 20-25 to find out the anthropometric proportion indices measurements and the shape classification for eyes, nose, face, upper vermilion and lower vermilion for Sri Lankans. Moreover the entire data set was categorized based on the weight categories according to BMI (Body Mass Index) values as BMI can be used to screen different weight categories.

The index measurements were measured with the use of Face SDK library as it is comparatively more reliable and accurate over manual measuring techniques whereas the domain expert's knowledge from the aesthetic and forensic art field were utilized in identifying the facial feature shapes. Afterwards by incorporating these parameters as shown in Fig. 1, 2D facial feature templates for face, eye, nose and mouth were created targeting Sri Lankan people and eventually these templates were then transferred into the system which can be used for the composite construction purpose.

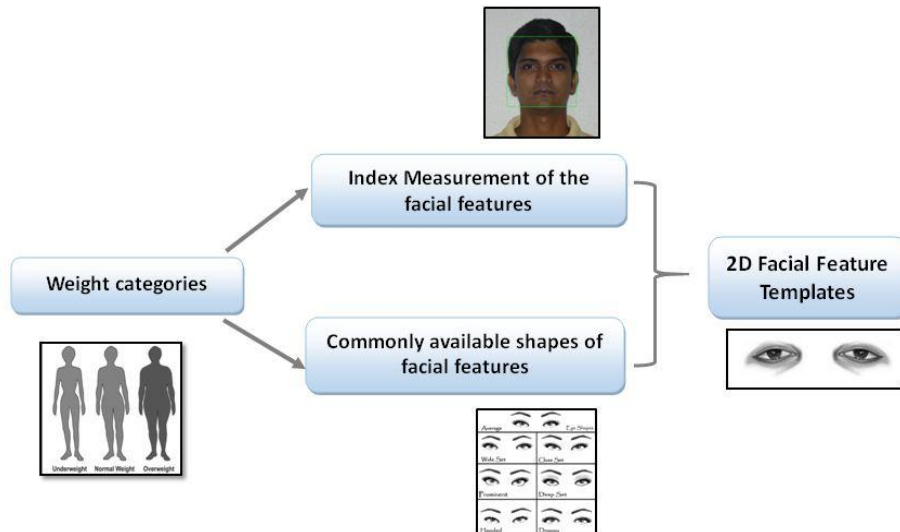


Figure 1: Facial feature template creation process by incorporating anthropometric indices and commonly available shapes

In addition, this system enables filtering the most possible feature templates based on the eyewitness description given with the age, height, weight and other criteria. Besides, this research study has identified the template positioning of each facial feature by analyzing the distance between the facial features and incorporating the standard divine proportions⁴ which is suitable for the Sri Lankan context. Finally, the face visualization process will perform iteratively until the eyewitness is satisfied with the ultimate composite image.

This solution has been evaluated⁵ with face pool and anthropometric index evaluation techniques where the face pool evaluation technique has obtained 70.19% accuracy. On the other hand the anthropometric index evaluation method obtained average of 84 % of out of the population who gave a response regarding the matching of the faces. This shows the significance of the accuracy level in composite images, when it uses the anthropometric indices measurements. Hence, this fully implemented computerized solution will significantly enhance the current manual facial composite procedure and eventually this proposed solution will benefit personnel to provide services to the criminal justice process such as law enforcement officers,

legal counsel and ensure that victimized person has quick access to justice.

ACKNOWLEDGEMENTS

Authors gratefully acknowledge the advisor Mr. Winnie Hettigoda, Senior lecturer of University of the Visual & Performing Arts and Senior Superintendent of Police Mr. Priyantha Jayakody, Director of Criminal Record Division in Sri Lanka who helped us in gaining the relevant domain knowledge.

REFERENCES

1. Personal communication, (2015) Manual Process of Suspect Identification through Facial Composite in Sri Lanka, Interviewee, Criminal records division of Sri Lanka police.
2. Frowd, C., McQuiston-Surrett, D., Anandaciva, S., Ireland, C. and Hancock, P. (2007) An Evaluation of US Systems for Facial Composite Production. *Ergonomics*, 50, 1987-1998. <http://dx.doi.org/10.1080/00140130701523611>
3. Rajapakse, R., Madugalla, A., Amarasinghe, I., Padmathilake, V., Dharmaratne, A., Sandaruwan, D. and Vidanapathirana, M. Facial Muscle Anatomy Based Approach for Forensic Facial Reconstruction in Sri Lanka. International Conference on Advances in ICT for Emerging Regions (ICTer)2012, Colombo, 27-35. <http://dx.doi.org/10.1109/icter.2012.6422828>.
4. Y. Jefferson, "Skeletal Types: key to unraveling the mystery of facial beauty and its biological significance," *Journal of General Orthodontics*, June 1996;vol. 7, pp. 10-12.
5. Jayasekara PB, Sivaneasharajah L, Perera MAS, **Perera J**, Karunaratne DD, Sandaruwan KD, Rajapakse RN. Facial Index Based 2D Facial Composite Process for Forensic Investigation in Sri Lanka. *Journal of Forensic Medicine and Anatomy Research*, (2016);4:7 - 16

A REVIEW OF THE USE OF SPHENO-OCCIPITAL SYNCHONDROSIS AS AN AGE INDICATOR AND ITS IMPLICATIONS FOR SRI LANKA

Induwara Gooneratne

Department of Forensic Medicine, Faculty of Medicine, University of Peradeniya, Sri Lanka

INTRODUCTION

A spheno – occipital synchondrosis is a cartilaginous joint, a growth centre found in the base of the skull between the basilar part of the occipital bone and the body of the sphenoid bone joining them together with a hyaline cartilage. This joint is important in cranio facial development for both vertical axis and horizontal plains resulting in the increase of facial height and width. The hyaline cartilage as usual is gradually replaced by bone with age and this very process has been used as a method to estimate the age of an unknown victim in forensic practice.

This paper attempts to review the existing literature on the use of spheno-occipital synchondrosis as an age indicator in forensic practice with a view to identify its strengths, weaknesses and possible challenges one may face in using it for practical purposes in Sri Lanka.

Although there are numerous other anthropological parameters such as cranial sutures, dental development chronologies, symphysis pubis surface used for estimating the age of an unknown, the use of spheno occipital synchondroses has also been attempted by many. The need for studying any potential entity in estimating the chronological age of an unknown in a forensic context will be useful as there are variations and competing views observed in every method available. Further, in instances where only the skull is available and perhaps when the teeth are missing due to various reasons, the use of spheno occipital synchondrosis can be helpful to substantiate

evidence to estimate the age of the victim. The basis of using this marker in estimating the age is the degree of closure, which has been detected as described below using varying methods.

METHODS

Researchers have used several methods to analyse the spheno-occipital synchondrosis with a view to estimate the age of fusion. The most oldest and commonest method that has been used is the direct inspection of the joint ectocranially and endocranially. In this process the researchers have either being binary in their assessment which means that they have indicated whether the joint is fused or not. In other instances the researchers have used a scoring system and indicated either not fused /open (0), partially fused (1) and then fused/closed (2). For example Shirley and Janz (2011) analyzed spheno-occipital joint macroscopically from outside and inside and gave a scoring for the degree of fusion.

Another common method that is used to study the spheno-occipital synchondrosis is the high resolution CT (Computer Tomography). In this method, which is known to provide a more detailed visualization of the joint than the direct method, the joint is analyzed and a scoring system is normally indicated to represent the degree of fusion. For example, El-Sheikh and Ramadan (2002) analysed skulls of an Arabian population using CT scans to estimate the age of closure of the spheno-occipital joint. Although CT image provides a detail information about the joint, in forensic practice, not everyone is equipped with such facilities. In this situation, some

researchers have attempted the use of radiological methods (X-rays), for example Sahni et al (1998) studied an Indian sample using X-rays. Further, histological studies especially using decalcification and then preparation of slides have also been attempted by researchers such as Tilander (1973) to visualise the speno occipital joint under a microscope.

DISCUSSION

Different authors seem to provide different age limits for the fusion of speno-occipital synchondrosis. The reasons for these varying predictions can be attributed to numerous reasons ranging from population variations, methodological differences, sample size differences, subjective elements in categorizing the degree of fusion either through direct method or using imaging techniques.

This joint has been noted to be important in forensic practice for reasons inter alia that it closes towards the latter part of adolescence. However, some authors for example Thilander (1973) and then Okomoto (1996) have indicated that the age of closure can even be towards as early as thirteen years. However the researches who used dry and direct inspection methods have suggested the closure of the joint takes place towards late adolescence. Krogman and Iscan note that the closure of speno-occipital synchondrosis occurs between 18 years to 23 years while Gray's Anatomy text book suggests that the fusion completes by twenty five years. Some researchers who had used laminographs have suggested that the closure can occur between 13 years to 16 years. These differences of opinions on the age at which the closure occurs stems mainly from the methods they have used. In other words, the opinion on the age at which the speno-occipital synchondrosis closes depends on the way one visualises the joint. For example those who examines the joint macroscopically directly will have an age range close to late adolescence as Krogman suggests while those who uses high resolution CT imaging and histo-morphological methods will observe a

younger age in which the said joint fuses. The reasons for this perhaps may be that the high resolution CT and histological methods provide more detail appearance of the joint whereas the direct method more or less provides a superficial appearance to which the examiner variation and subjectivity can also be added. It is important to note that Elshark et al's study where they used high resolution CT imaging, the researchers have observed complete closure even at 11 years of age of the individual.

Further, researchers have observed that there is a gender difference at which the fusion of the joint occurs. Thilander et al (1973) observed that in females the speno-occipital joint closes about two years earlier than that of a male. This means that it is important to have norms of closure of speno-occipital synchondrosis of males and females separately and that it is not desirable to apply the closing age of a male to a female or vice versa. Further, researchers have observed different age limits of fusion of the said joint in different populations. This suggests that it is important to have average data of closing times of the joint for different populations. As Krishan and Kanchan(2013) suggests different ethnic groups in India have shown different ages of closure of the speno-occipital joint.

The literature suggests that the fusion of the joint begins endocranially and extends to ectocranial surface. This means that there can be age difference between the times of fusion observed macroscopically at ectocranial and endocranial surfaces. Further, as indicated above there is a significant variation observed on the age of fusion among males and females. Additionally researchers have observed variations of the age of fusion of speno-occipital synchondrosis between various ethnic groups. While there is marked evidence in the literature to suggest variations of the age of fusion using the same method, the use of different methods by different researchers have shown even more significant differences of the fusion times of the speno-occipital joint. As shown above those who used high resolution CT images and

histological methods have observed lower ages of fusion compared to those who have used macroscopic direct methods to observe fusion.

The macroscopic observation of fusion or the detection of the degree of fusion to an untrained eye can be challenging so that the opinion can be subjective. The concern as to what degree of fusion one takes as 'complete' and whether total obliteration or total absence of a demarcation at the spheno-occiput junction one takes as 'complete' are also concerns one needs to consider especially when one uses the macroscopic direct observation methods.

Some researchers have attempted to evaluate the degree of fusion rather than depending on the binary outcome at the end – fused complete or unfused/open. In evaluating the degree of fusion many have attempted to score the degree of fusion. There is no uniformity in the scoring system across the research published. Some have tried to provide a binary outcome as complete/fused and unfused/incomplete. Others have attempted to provide a process where as they have given scores for complete/fused, then fusing/partially fused and then unfused/open.

The sample sizes of the studies published vary significantly. Some studies have as less samples as twenty one. There is unequal distribution of sex among these samples. Then, it is important to consider if these results are in fact represent the populations they come from to make a generalised idea about the populations they derived from. Despite the fact that populations can significantly vary based on their ethnicities, genetics, nutritional patterns and geographical locations, it seems that some attempt to extrapolate and apply results of published studies without having their own standards for each populations with adequate amount of sample size.

Despite many efforts, it was not possible to find any research conducted in Sri Lanka on Sri Lankan population evaluating the spheno-

occipital synchondrosis for age estimation. As Sri Lankan population is a unique one, it is necessary that we in Sri Lanka survey main ethnic groups for the closing times of this joint if at all practitioners would want to use it as an indicator for age assessment of the unknown.

CONCLUSION

The above review and discussion indicates that the spheno-occipital synchondrosis is not a very reliable indicator of the age at death. However, if one attempts to use it in the absence of other reliable parameters or to substantiate the age with other parameters, it is important to consider the method the researchers have used, the gender of the sample population, the sample size used in the study, the population from which the same of the original study. If these concerns are not considered, the outcome opinion of the age can be misleading.

REFERENCES

1. Shirley NR, Jantz RL. Spheno-occipital synchondrosis fusion in modern Americans. *J Forensic Sci.* 2011;56:580–5
2. Sahni D, Jit I, Neelam, Suri S. Time of fusion of the basisphenoid with the basilar part of the occipital bone in northwest Indian subjects. *Forensic Sci Int.* 1998;98:41–5.
3. Thilander B, Ingervall B. The human spheno-occipital synchondrosis. II. A histological and microradiographic study of its growth. *Acta Odontol Scand.* 1973;31:323–34.
4. Okamoto K, Ito J, Tokiguchi S, Furusawa T. High-resolution CT findings in the development of the sphenooccipital synchondrosis. *AJNR Am J Neuroradiol.* 1996;17:117–20.
5. Krogman WM, Iscan YM. 2nd ed. Springfield, Illinois, USA: Charles C. Thomas Pub Ltd; 1986. The human skeleton in forensic medicine
6. .El-Sheikh ME, Ramadan S. Age of closure of the spheno-occipital synchondrosis in the Arabian Gulf region. *Forensic Physical Anthropology Proceedings of American Academy of Forensic Sciences 2002-2011.*
7. Krishnan K, Kanchan T Evaluation of Spheno Occipital Synchondrosis. *J of Forensic Dent Sci.* 2013.

INSTRUCTIONS TO AUTHORS

Sri Lanka Journal of Forensic Medicine, Science & Law (SLJFSL) publishes original research papers, reviews, points of view, case reports, technical notes and letters to the editor, in all areas of Forensic Medicine, Forensic Sciences & relevant Law & Ethics.

Material received is assumed to be submitted exclusively to this journal. All papers will be peer reviewed. The editor reserves the right to amend style, correct English language, and do editorial corrections where necessary, and determine priority and time of publication. When submitting papers, authors are advised to keep copies of the manuscripts and to include a covering letter in which all authors have consented for the publication of the article in the Sri Lanka Journal of Medicine, Science and Law.

A soft copy of the manuscript, including figures and tables, should be submitted to the editor in Microsoft Word format: Dr. Induwara Gooneratne, Editor, SLJFMSL, Dept. of Forensic Medicine, Faculty of Medicine, University of Peradeniya (induwarag@yahoo.com). The paper should be typesetted with double spacing. All pages should be numbered. The manuscript should be divided into the following sections, each of which should begin on a separate page: Title Page, Summary/ Abstract, Text, Acknowledgements, References, Tables, Figures and Legends. Authors are encouraged to email or e-submit (through the webpage) articles in the above format. The title page should give the full title, names of authors with qualifications, posts held during the study, department(s) and institution(s) where the work was carried out, and the name and full address (including telephone number, emails) of the author for correspondence.

The summary/abstract should not exceed 250 words and should illustrate what was done, the main findings and conclusions. Up to five Key words should be given under the Summary.

The text of full papers should be divided into Introduction, Materials and Methods, Results, and Discussion. Only generic names of drugs should be given, if applicable. Abbreviations should be spelt out when first used in the text. Scientific measurements should be given in SI units. Statistical methods should be specified in the methods section and any term which is not in common usage should be referenced.

Tables and figures should be referred to in the order of appearance in the text in Arabic numerals within parentheses, e.g. (Fig. 1). Tables with brief titles should be typed on separate pages. Figures should be used only when data cannot be expressed clearly in any other form. Photographs should clearly show the figure number and caption, and attached as jpg files or inco-operated into the MS word document.

References should be in the Vancouver style, and numbered consecutively using Arabic numerals within parentheses in the order in which they appear in the text.

Peer Reviewing Process

Each article submitted will be reviewed by two reviewers : One member from the journal's editorial board and one external expert in the field relevant to the article. The process will be double blinded; neither the author nor the reviewer will be informed each other's identity. The editor has the right to accept or reject articles based on reviewers' comments.

Plagiarism

Authors are advised to refrain from any form of plagiarism. All sources must be correctly cited. All articles may be subjected to a plagiarism detection software by the publisher/editor.

Fees

No fee will be charged for accepting, reviewing or publishing articles. However if the article requires extensive correction of English language, the editor may recommend the author to consult an English language expert at the author's expense.

Reprints of articles can be supplied at an approved cost. Inquiries regarding advertisements & subscription should be addressed to, Dr. Induwara Gooneratne, Editor, SLJFSL Dept. of Forensic Medicine Faculty of Medicine, University of Peradeniya Sri Lanka. Individual copies of the Journal are available at Rs.350/- each. All cheques and drafts should be drawn in favour of the 'Sri Lanka Journal of Forensic Medicine, Science & Law, Dept. of Forensic Medicine, Faculty of Medicine.

It must be noted that the journal is also published as an open access e journal through Sri Lanka Journals online.

Submission Preparation Checklist

As part of the submission process, authors are required to comply with all of the following, Submissions that do not adhere to these guidelines may be rejected.

1. The submission has not been previously published, nor it is before another journal for consideration concurrently.
2. The submission file is in Microsoft Word format.

3. All references have been provided correctly.
4. The text is double-spaced; uses a 12-point font; Illustrations, figures, and tables are placed within the text at the appropriate points, rather than at the end.
5. The text adheres to the stylistic academic and bibliographic requirements outlined in the Author Guidelines.
6. Corresponding author has obtained consent from all authors to publish.
7. Ethical clearance and other legal or administrative permissions have been already taken by the authors where necessary for conducting/publishing the research.
8. The authors are responsible for the work carried out in the study.

Copyright Notice



This publication uses Creative Commons Attribution-Non Commercial License as above: By submitting articles to the journal, authors give the editor the right to edit and publish articles. Information in this journal may be shared or adapted by readers for non-commercial purposes only, provided the source is correctly cited.

Privacy Statement

The names and email addresses entered in this journal site will be used exclusively for the stated purposes of this journal.

Editorial Assistance:

Dr. Ameen Izzath

Cover Design & Typesetting:

Ms. Vinodani Dharmasena, Dept. of Forensic Medicine, Peradeniya

